

# Intrahepatic cholestasis in pregnancy: Increased surveillance and the role of bile acids in a patient with history of fetal demise

Noah Ryan Begley, Abdalyz Frias Beltran

## ABSTRACT

Intrahepatic cholestasis of pregnancy (ICP) is a known risk for fetal demise and premature delivery and presents in up to one-third of all pregnancies. Cases traditionally present with pruritis, elevated bile acids, and/or elevated liver enzymes. We describe the case of a third-trimester patient with history of fetal demise and ICP that would have gone unnoticed based on laboratory reporting and symptomatic delay. The patient's symptoms presented weeks after bile acid findings and when tested again were sub-diagnostic. The patient declined pharmacological intervention and opted to induce labor during her 37th week where she delivered a healthy term child. The diagnosis was further complicated when the types and thresholds for bile acids varied between facilities. Our case highlights the importance timely assessment of itching in pregnant patients and the need to assess lab values objectively in the context of clinical features.

**Keywords:** Antenatal care, Cholestasis of pregnancy, Liver enzymes, Pruritis, Serum bile acids

### How to cite this article

Begley NR, Beltran AF. Intrahepatic cholestasis in pregnancy: Increased surveillance and the role of bile acids in a patient with history of fetal demise. J Case Rep Images Obstet Gynecol 2022;8:100102Z08NB2022.

Noah Ryan Begley<sup>1</sup>, Abdalyz Frias Beltran<sup>1</sup>

**Affiliations:** <sup>1</sup>School of Medicine, Universidad Autonoma de Guadalajara, Phoenix, Arizona, USA.

**Corresponding Author:** Noah Ryan Begley, School of Medicine, Universidad Autonoma de Guadalajara, 12745 W Bloomfield Rd, El Mirage, AZ 85335, USA, Email: noahrbegley@gmail.com

Received: 14 October 2021

Accepted: 05 December 2021

Published: 15 January 2022

Article ID: 100102Z08NB2022

\*\*\*\*\*

doi: 10.5348/100102Z08NB2022CR

## INTRODUCTION

Nearly a quarter of pregnant patients experience pruritus significant enough to report to their provider. Most cases are dermatological in origin and present with some evidence. Intrahepatic cholestasis of pregnancy (ICP) is one cause of pruritus that presents without a rash and has more severe consequences than other causes of itching. The risk is higher for Latin females who have an incidence of up to 15% versus the general obstetric population 0.3–0.5% [1]. The typical presentation of ICP is second or third trimester and includes pruritus in the palms and soles that worsens at night. Other symptoms of ICP include abdominal pain, nausea, poor appetite, and subclinical steatorrhea [2].

The causes of ICP are poorly understood, but are believed to be a combination of genetic, hormonal, and environmental factors. Mutations in phospholipid and bile salt export pumps found in the liver and placentas of ICP patients are believed to be factors [3–5]. An increased amount of the smooth muscle relaxant estrogen during pregnancy is another known contributor to stasis and the buildup of bile acids. Increased progesterones conjugation in the hepatic export system leads to inflammation and could play an additional role.

During pregnancy, serum bile acids within the fetus are slightly higher than those in the maternal circulation where they are ultimately transferred for excretion [6]. In ICP, the fetomaternal concentration gradient is reversed and is known to increase risk of fetal complications such as stillbirth, spontaneous preterm birth, and vasospasms leading to abnormal electrocardiogram (ECG) findings [7]. In particular, it has been shown that fetal cardiomyocytes have increased susceptibility to and

incidence of tachycardia, bradycardia, atrial flutter, and supraventricular tachycardia when exposed to elevated bile acids [8].

Total bile acids (TBA) values  $>10\text{--}20$   $\mu\text{mol/L}$  (varies with lab) during second and third trimesters are considered diagnostic [9]. Evaluation includes history and physical exam and complete blood count (CBC), liver function tests (LFTs), TBA, and weekly fetal biophysical profile (BPP). The debate on whether TBA should be collected fasting or postprandial has remained. Liver function tests are elevated in up to 60% of cases and represent bile acid induced dysfunction of the hepatobiliary tree and damage to hepatocytes. Collection of LFTs is recommended but elevated levels are not required for diagnosis and their role in management of ICP is not established. More common causes of itching such as dermatitis, and more severe causes such as HELLP (hemolysis, elevated liver enzymes, and low platelet count) syndrome must also be ruled out.

The use of ursodeoxycholic acid (UDCA) has demonstrated efficacy in the treatment of symptomatic ICP cases and, reducing the likelihood of neonatal cardiac abnormalities [7]. Should bile acids reach or exceed  $100$   $\mu\text{mol/L}$ , and symptoms are refractory to treatment or the patient has a history of intrauterine demise due to ICP delivery starting at  $36$   $0/7$  has shown to reduce the risks of stillbirth (Ovadia). For those with TBA between  $40$  and  $99$   $\mu\text{mol/L}$  or persistent symptoms delivery between  $36$   $0/7$  and  $39$   $0/7$  is recommended [10]. Postpartum bile acids should be collected at  $4\text{--}6$  weeks to reevaluate a patient's status. If hepatobiliary dysfunction is persistent by laboratory standards a referral to gastroenterology is warranted [4]. Although not routinely obtained, biopsy histopathology typically demonstrates stasis and plugging within hepatic bile ducts (Figures 1 and 2). Succeeding pregnancies should be monitored for ICP given there is a  $60\text{--}90\%$  chance of recurrence [13].

## CASE REPORT

A 30-year-old G5P1T3L3 female patient with a history of unexplained fetal demise presented to the clinic at  $37$   $+1$  having just been discharged from a nearby unaffiliated hospital's obstetrics department. The patient had an uneventful pregnancy to that point but four days earlier presented to the hospital obstetrics floor complaining of whole-body itching with pronounced pruritus on the hands and feet. In the office, the physical exam was unremarkable except for scratch marks on the lateral aspect of one leg. Fetal heart tones were within normal limits (WNL) and she reported fetal movements daily with no abdominal pain or vaginal bleeding. Urinalysis was unremarkable for signs of infection or preeclampsia and the patient was normotensive. A review of her hospital labs showed a bile TBA of  $7$   $\mu\text{mol/L}$  including fractionated bile acids (FBA) and values of aspartate aminotransferase (AST)  $47$   $\text{U/L}$ , alanine transaminase (ALT)  $44$   $\text{U/L}$ , and elevated alkaline phosphatase (ALP)  $225$   $\text{U/L}$ . A routine

complete metabolic panel (CMP) obtained 3 weeks earlier while the patient was asymptomatic showed normal LFTs and a TBA consistent with ICP at  $11$   $\mu\text{mol/L}$  although that value was not considered elevated by that lab's reference ranges. At presentation, the patient was now symptomatic and a repeat CMP with TBA was taken in the clinic and showed TBA had decreased to  $4$   $\mu\text{mol/L}$  and LFTs were unremarkable. Although values fell below the diagnostic threshold the patient's itching worsened and was consistent with ICP. The patient declined pharmacological intervention and instead she presented to the hospital with worsening of her itching. Given earlier lab confirmation of ICP, refractory symptoms, and history of fetal demise a decision was made with the patient to undergo induction at  $37$   $3/7$ . A healthy full-term baby was delivered without incident. At a 3-week follow-up, the patient reported cessation of pruritus and a thriving newborn.

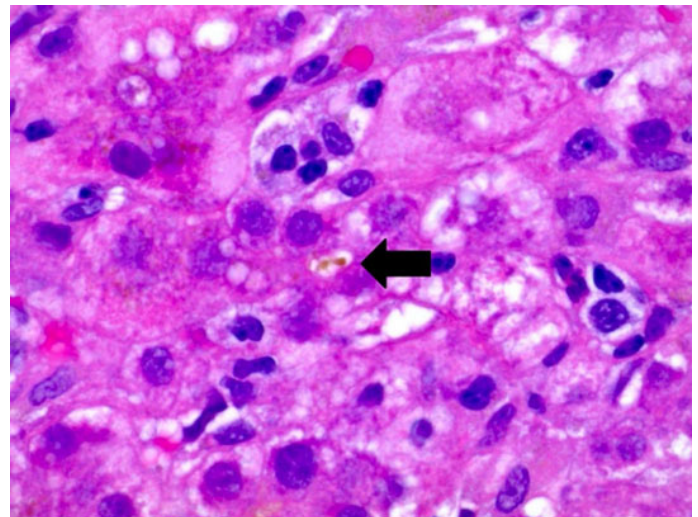


Figure 1: Intracannicular cholestasis (arrow).

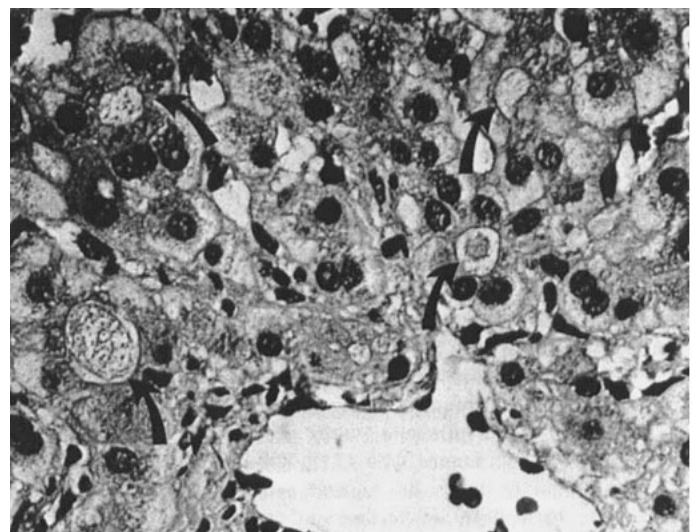


Figure 2: Bile plugging within hepatic canniculi and hepatocytes (curved arrow) [11, 12].

## DISCUSSION

In this case, we found that different labs measured different acid types and had different thresholds for “elevated” [14]. Further comparison with labs across the country revealed that the values changed even more dramatically with distance [15]. Manzotti et al. found that neither value was significantly sensitive or specific for the diagnosis of ICP or the management of symptoms [16]. Perinatology researchers have suggested that neutrophil to leukocyte ratio could serve as a more specific measurement of disease severity given the role inflammation plays in ICP [17]. A more sensitive or specific sign would be clinically helpful, however, we agree that future efforts should focus on establishing consistency for reference ranges between laboratories and the significance of fractionated bile acids. Moreover, it is not clear when the benefits of UDCA are maximized and should be evaluated on a chronometric scale to better understand the benefits and to reduce the iatrogenic effects of pharmacological intervention and preterm delivery. These variables in highlight the need for physicians to consider the clinical picture in full and emphasize the need to make timely medical decisions given the known morbidity and mortality risks the pathology poses.

Obstetricians are in a position to survey risk factors unique to their patients such as those who have had a cholestatic response to oral contraceptives [18] and have the benefit of more frequent visits. At-risk populations should not exclude patients who have undergone cholecystectomy as postcholecystectomy syndrome (PCS) occurs in 0.1–1.5% of the population, and up to 70% experience intrahepatic cholestasis [19]. Anxiety is another risk factor associated with increased perinatal morbidity and should be evaluated appropriately [20]. More frequent monitoring could relieve these symptoms and support the need for increased surveillance.

## CONCLUSION

Patients suspected of intrahepatic cholestasis should have bile acids and liver enzymes assessed objectively in reference to values cited in the literature versus standard values quoted in each laboratory. Patients with this pathology should be evaluated closely and promptly offered all available options for treatment and delivery to avoid life-threatening risks posed to the fetus.

## REFERENCES

1. Kirby B. Understanding intrahepatic cholestasis of pregnancy [Internet]. The Society for Maternal-Fetal Medicine. [cited 2021 Mar 8]. [Available at: <https://www.smfm.org/publications/96-understanding-intrahepatic-cholestasis-of-pregnancy>]
2. Pusl T, Beuers U. Intrahepatic cholestasis of pregnancy. *Orphanet J Rare Dis* 2007;2:26.

3. Nayagam JS, Williamson C, Joshi DJ, Thompson RJ. Review article: Liver disease in adults with variants in the cholestasis-related genes ABCB11, ABCB4 and ATP8B1 [Internet]. *Alimentary pharmacology & therapeutics*. U.S. National Library of Medicine; 2020 [cited 2021 Apr 11]. [Available at: <https://pubmed.ncbi.nlm.nih.gov/33070363/>]
4. Pillarisetty LS. *Pregnancy Intrahepatic Cholestasis*. In: StatPearls. Treasure Island (FL): StatPearls Publishing; 2021.
5. Wang H, Yan Z, Dong M, Zhu X, Wang H, Wang Z. Alteration in placental expression of bile acids transporters OATP1A2, OATP1B1, OATP1B3 in intrahepatic cholestasis of pregnancy. *Arch Gynecol Obstet* 2011;285(6):1535–40.
6. Williamson C, Miragoli M, Sheikh Abdul Kadir S, et al. Bile acid signaling in fetal tissues: Implications for intrahepatic cholestasis of pregnancy. *Dig Dis* 2011;29(1):58–61.
7. Vasavan T, Deepak S, Jayawardane IA, et al. Fetal cardiac dysfunction in intrahepatic cholestasis of pregnancy is associated with elevated serum bile acid concentrations. *J Hepatology* 2021;74(5):1087–96.
8. Williamson C, Gorelik J, Eaton BM, Lab M, Swiet Mde, Korchev Y. The bile acid taurocholate impairs rat cardiomyocyte function: A proposed mechanism for intra-uterine fetal death in obstetric cholestasis. *Clin Sci* 2001;100(4):363–9.
9. Egan N, Bartels A, Khashan AS, et al. Reference standard for serum bile acids in pregnancy. *BJOG* 2012;119(4):493–8.
10. Ovadia C, Seed PT, Sklavounos A, et al. Association of adverse perinatal outcomes of intrahepatic cholestasis of pregnancy with biochemical markers: Results of aggregate and individual patient data metaanalyses. *Lancet* 2019;393(10174):899–909.
11. Wongjarupong N, Bharmal S, Lim N. Never too soon: An unusual case of intrahepatic cholestasis of pregnancy at five weeks gestation. *Cureus* 2020;12(9).
12. Rolfes DB, Ishak KG. Liver disease in pregnancy. *Histopathology* 1986;10(6):555–70.
13. Intrahepatic Cholestasis of Pregnancy (ICP). American Liver Foundation 2021. [Available at: <https://liverfoundation.org/for-patients/about-the-liver/diseases-of-the-liver/intrahepatic-cholestasis-of-pregnancy/#1506367925144-07592f1-111e>]
14. Test ID: BAPS. Bile acid profile, serum. Mayo Clinic Laboratories 2021. [Available at: <https://www.mayocliniclabs.com/test-catalog/Clinical+and+Interpretive/62538>]
15. Lang T, McKeown G, Hunter A. Biochemical investigation and clinical management of obstetric cholestasis (OC): How useful is bile acid quantification? *Archives of Disease in Childhood - Fetal and Neonatal Edition* 2012;97(Suppl 1):A50–1.
16. Manzotti C, Casazza G, Stimac T, Nikolova D, Gluud C. Total serum bile acids or serum bile acid profile, or both, for the diagnosis of intrahepatic cholestasis of pregnancy. *Cochrane Database Syst Rev* 2019;(7).
17. Kirbas A, Biberoglu E, Daglar K, et al. Neutrophil-to-lymphocyte ratio as a diagnostic marker of intrahepatic cholestasis of pregnancy. *Eur J Obstet Gynecol Reprod Biol* 2014;180:12–5.

18. Williamson C, Geenes V. Intrahepatic cholestasis of pregnancy. *Obstet Gynecol* 2014;124(1):120–33.
19. Barbier L, Souche R, Slim K, Ah-Soune P. Long-term consequences of bile duct injury after cholecystectomy. *J Visc Surg* 2014;151(4):269–79.
20. Orr ST, Reiter JP, Blazer DG, James SA. Maternal prenatal pregnancy-related anxiety and spontaneous preterm birth in Baltimore, Maryland. *Psychosom Med* 2007;69(6):566–70.

\*\*\*\*\*

### Acknowledgments

Thank you to Doctor David M. Greenspan, MD for his mentorship, guidance, and his passion for obstetrics that inspired this collaboration. Thank you to Doctor Lourdes Gonazlez, MD for your support and encouragement to complete this review.

### Author Contributions

Noah Ryan Begley – Conception of the work, Design of the work, Acquisition of data, Interpretation of data, Drafting the work, Revising the work critically for important intellectual content, Final approval of the version to be published, Agree to be accountable for all aspects of the work in ensuring that questions related to the accuracy or integrity of any part of the work are appropriately investigated and resolved

Abdalyz Frias Beltran – Conception of the work, Interpretation of data, Drafting the work, Revising the work critically for important intellectual content, Final

approval of the version to be published, Agree to be accountable for all aspects of the work in ensuring that questions related to the accuracy or integrity of any part of the work are appropriately investigated and resolved

### Guarantor of Submission

The corresponding author is the guarantor of submission.

### Source of Support

None.

### Consent Statement

Written informed consent was obtained from the patient for publication of this article.

### Conflict of Interest

Authors declare no conflict of interest.

### Data Availability

All relevant data are within the paper and its Supporting Information files.

### Copyright

© 2022 Noah Ryan Begley et al. This article is distributed under the terms of Creative Commons Attribution License which permits unrestricted use, distribution and reproduction in any medium provided the original author(s) and original publisher are properly credited. Please see the copyright policy on the journal website for more information.